


Section 4

Left heart catheterization and percutaneous transfemoral coronary angiography

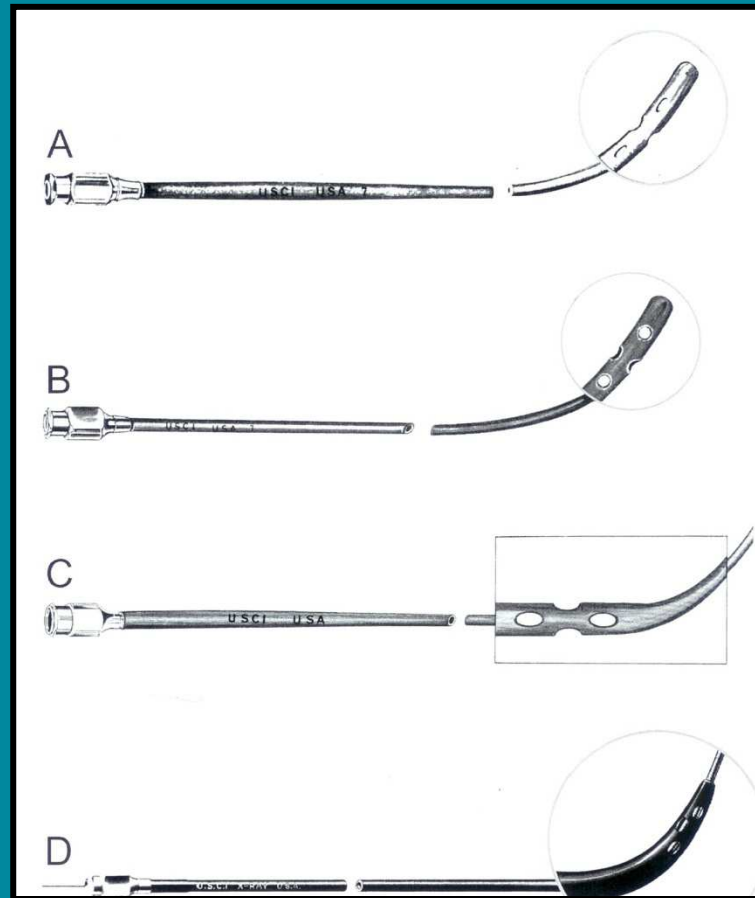
Martial G. Bourassa

Left heart catheterization and percutaneous transfemoral coronary angiography




Sven-Ivar Seldinger

Left heart catheterization and percutaneous transfemoral coronary angiography




Modifications to the initial Cournand catheter

Left heart catheterization and percutaneous transfemoral coronary angiography




Seldinger needle

Left heart catheterization and percutaneous transfemoral coronary angiography



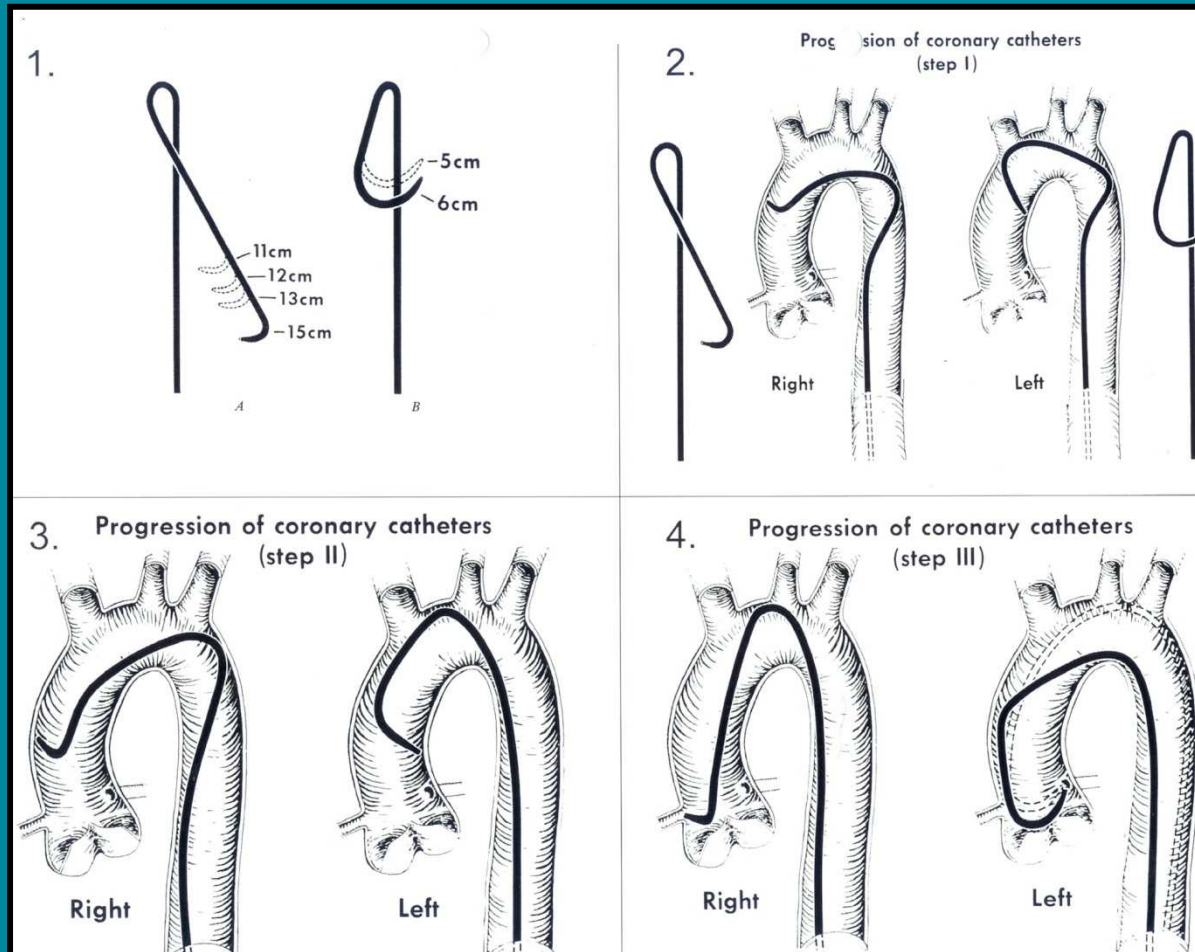
Teflon-coated spring coil guide wires

Left heart catheterization and percutaneous transfemoral coronary angiography



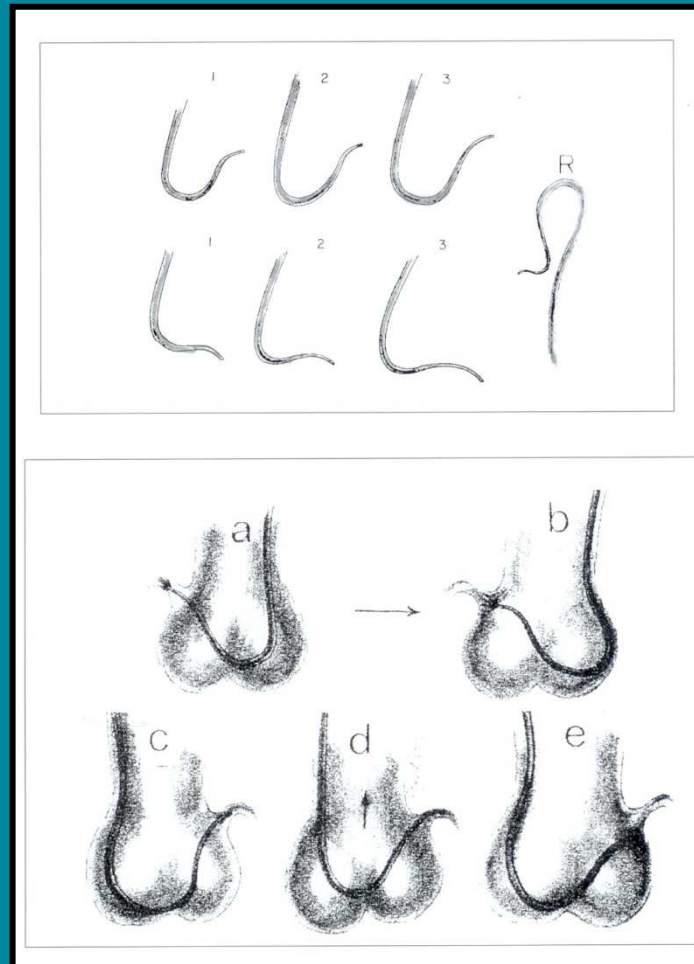
Pigtail catheter

Left heart catheterization and percutaneous transfemoral coronary angiography



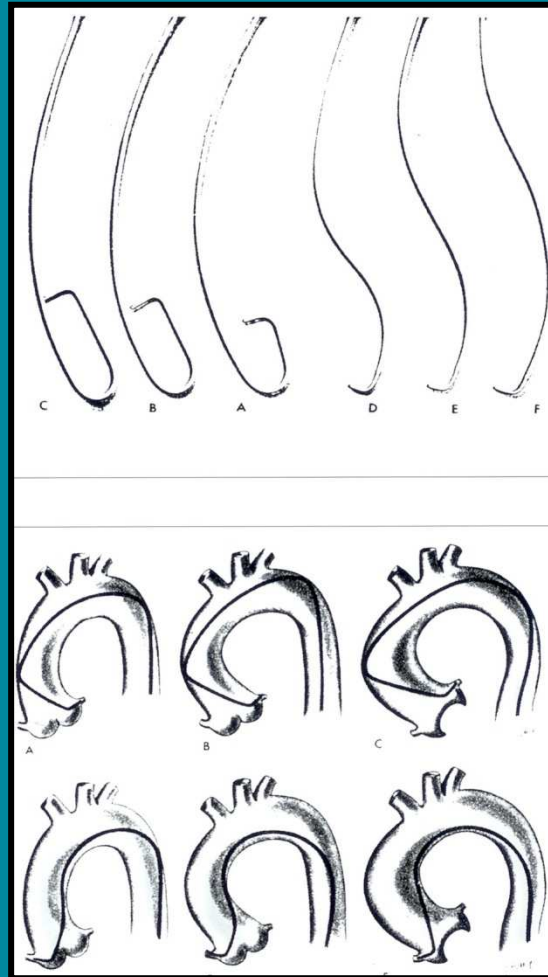
Preformed coronary catheters: design, shapes and techniques

Left heart catheterization and percutaneous transfemoral coronary angiography



Preformed coronary catheters: design, shapes and techniques

Left heart catheterization and percutaneous transfemoral coronary angiography



Preformed coronary catheters: design, shapes and techniques