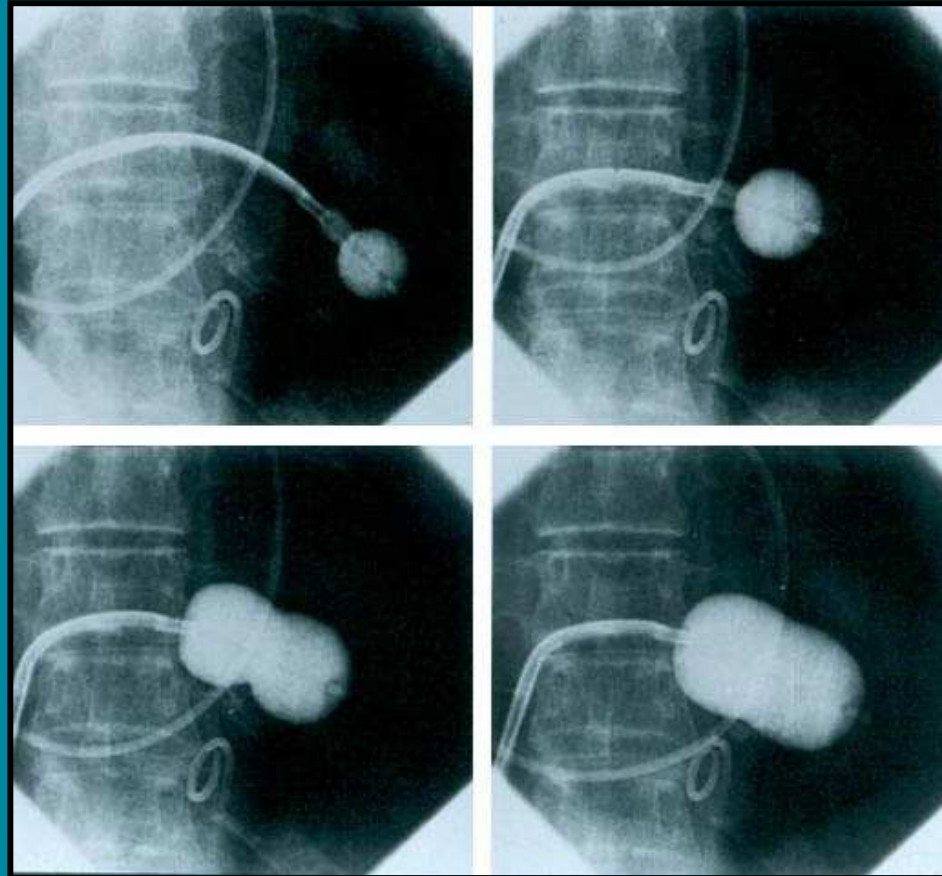


Section 23

Percutaneous mitral balloon valvuloplasty using the double-balloon technique: immediate and long-term follow-up results

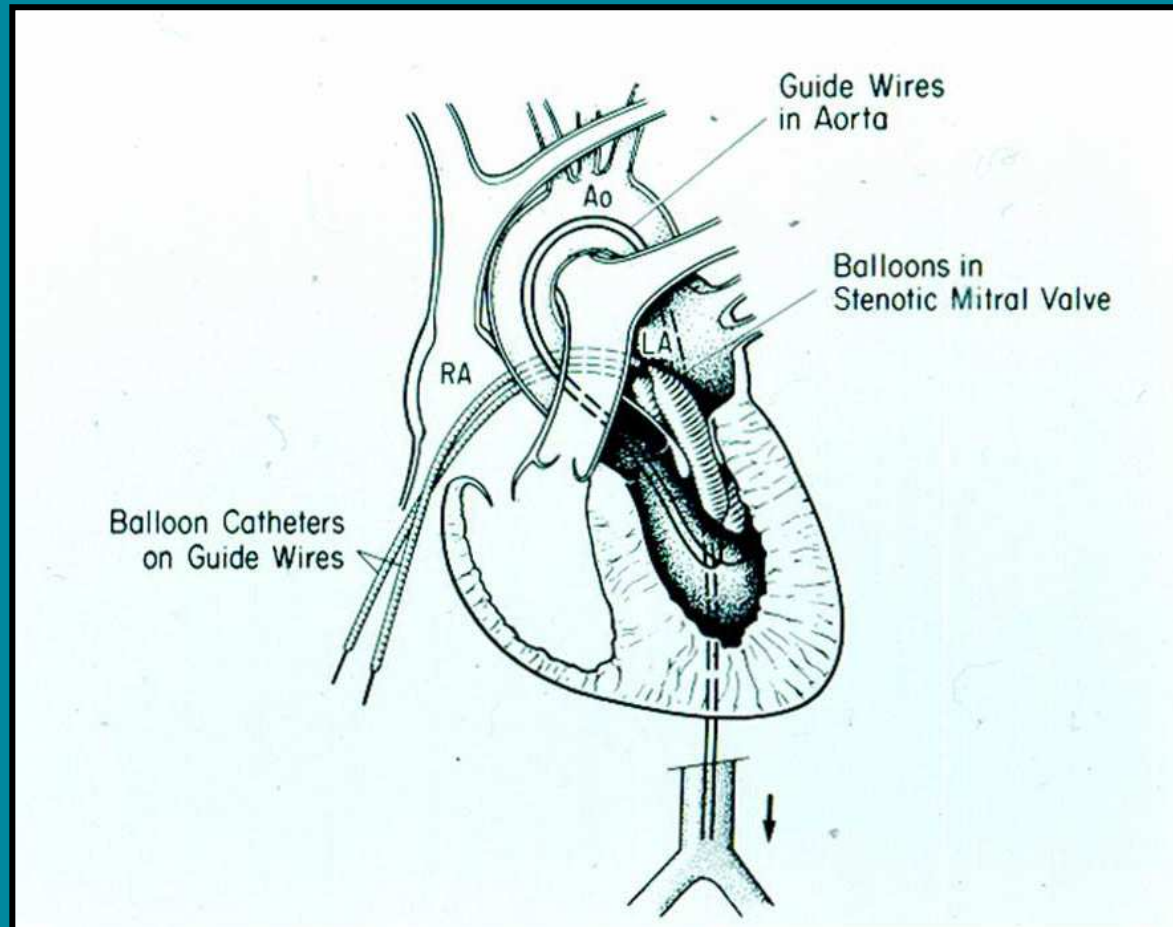
Igor F. Palacios

**Percutaneous mitral balloon valvuloplasty using the double-balloon technique:
immediate and long-term follow-up results**



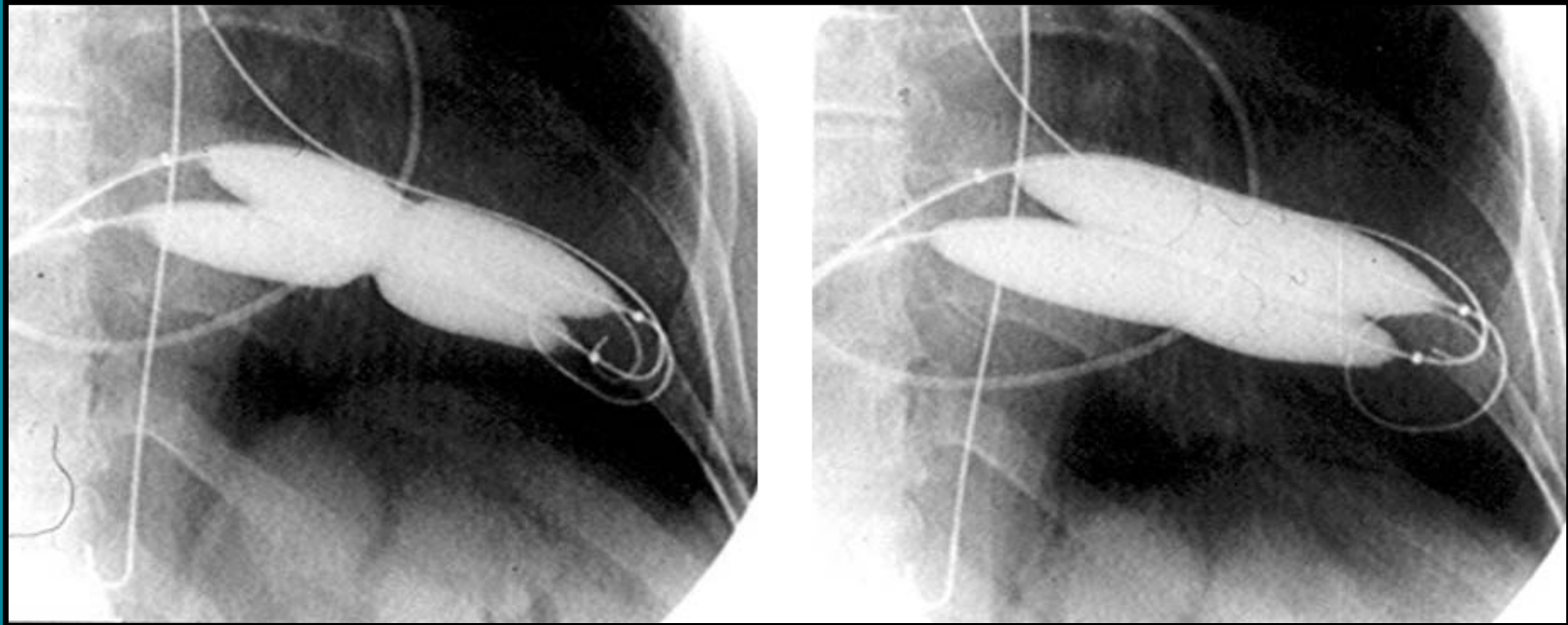
The Inoue balloon technique of PMV

Percutaneous mitral balloon valvuloplasty using the double-balloon technique: immediate and long-term follow-up results



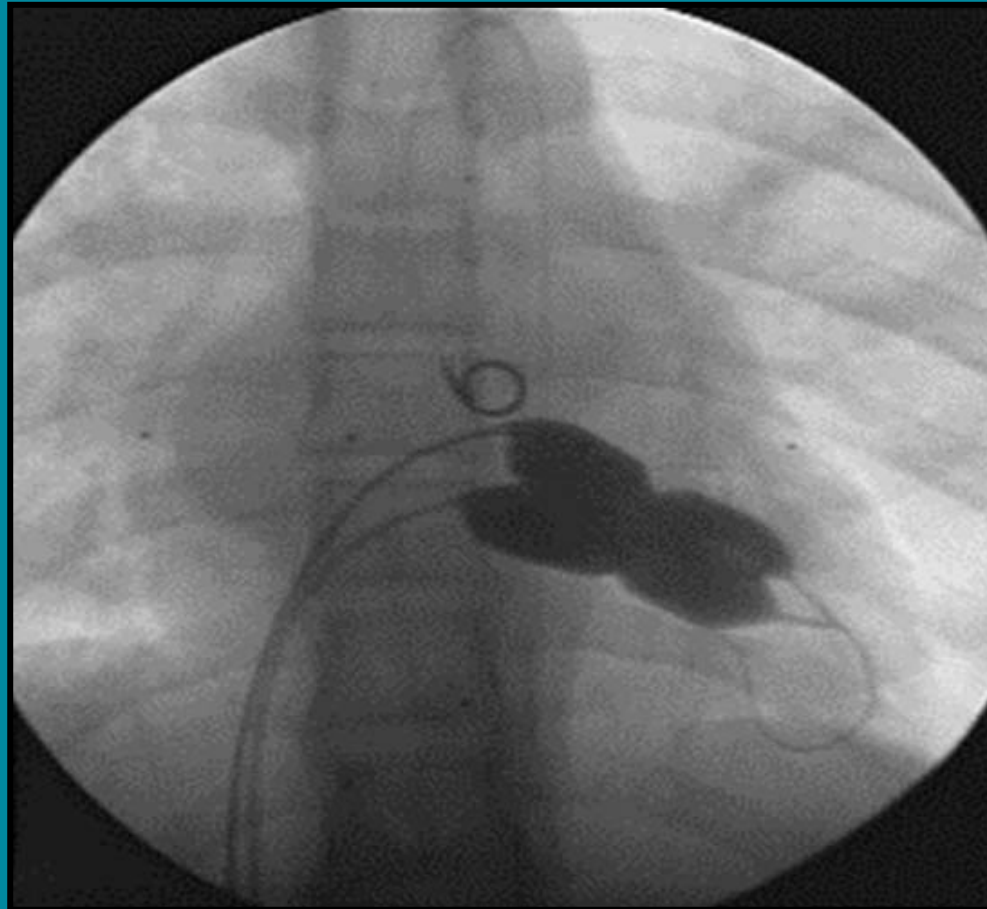
Diagrammatic representation of the double-balloon technique of PMV

**Percutaneous mitral balloon valvuloplasty using the double-balloon technique:
immediate and long-term follow-up results**



Double-balloon PMV

**Percutaneous mitral balloon valvuloplasty using the double-balloon technique:
immediate and long-term follow-up results**



The Multi-Track technique of PMV

**Percutaneous mitral balloon valvuloplasty using the double-balloon technique:
immediate and long-term follow-up results**

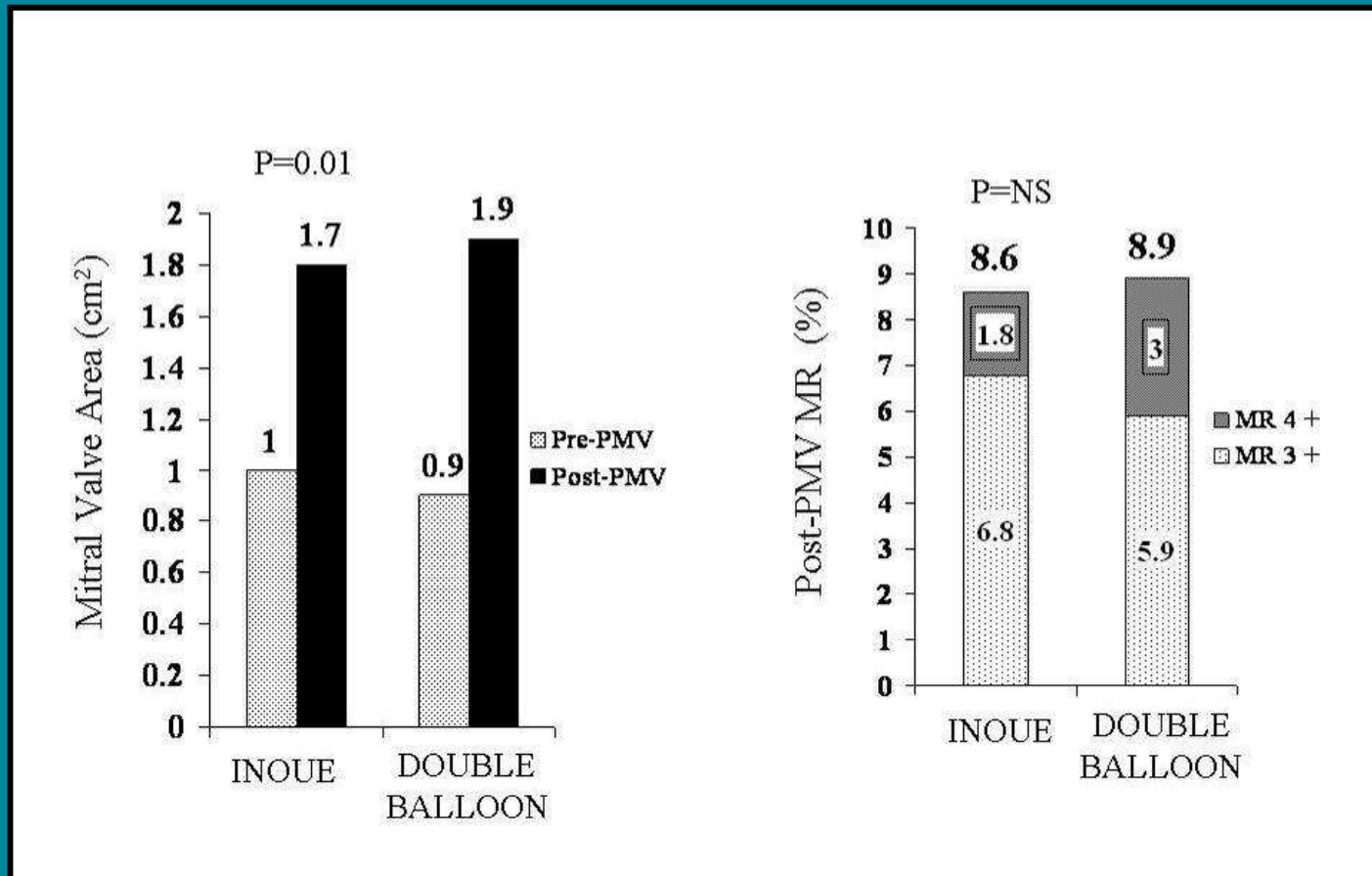
(cm²)

Balloon # 1

	0	15	18	20
Balloon # 2 15	1.77	4.02	4.89	5.55
18	2.54	4.89	5.78	6.46
20	3.14	5.55	6.46	7.14
23	4.15	6.57	7.55	8.27
25	4.91	7.46	8.41	9.11

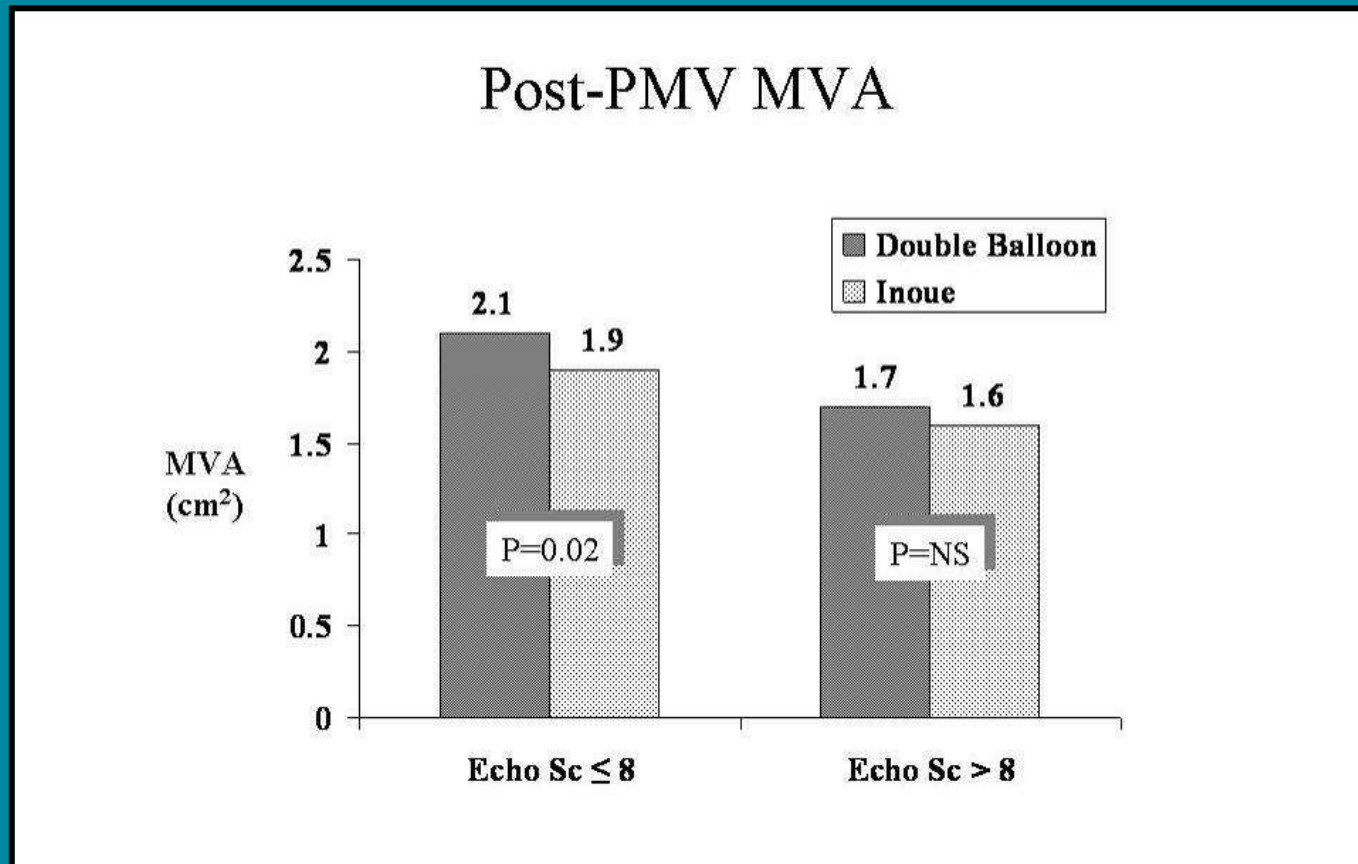
The effective balloon dilating area (EBDA) for any balloon combination used with the double-balloon technique

Percutaneous mitral balloon valvuloplasty using the double-balloon technique: immediate and long-term follow-up results



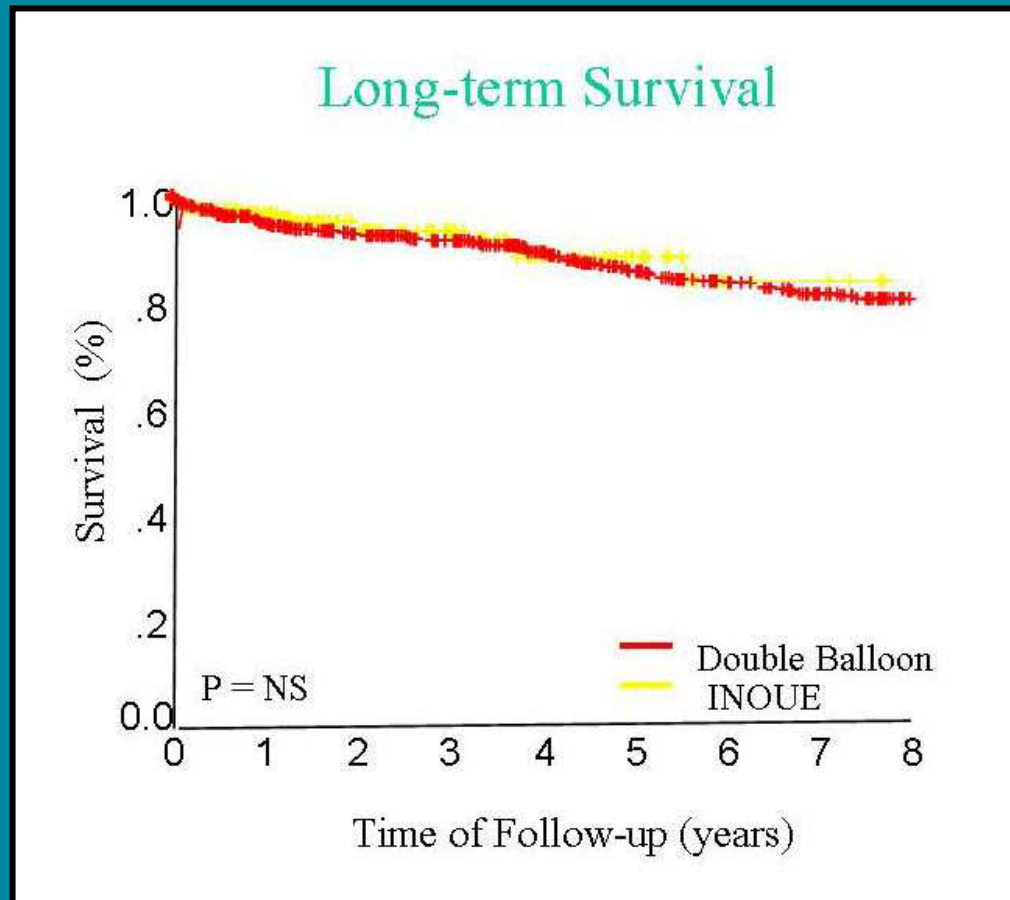
Comparison of post-PMV MVA and post-PMV mitral regurgitation between patients undergoing PMV using the double-balloon technique versus those with Inoue PMV

Percutaneous mitral balloon valvuloplasty using the double-balloon technique: immediate and long-term follow-up results



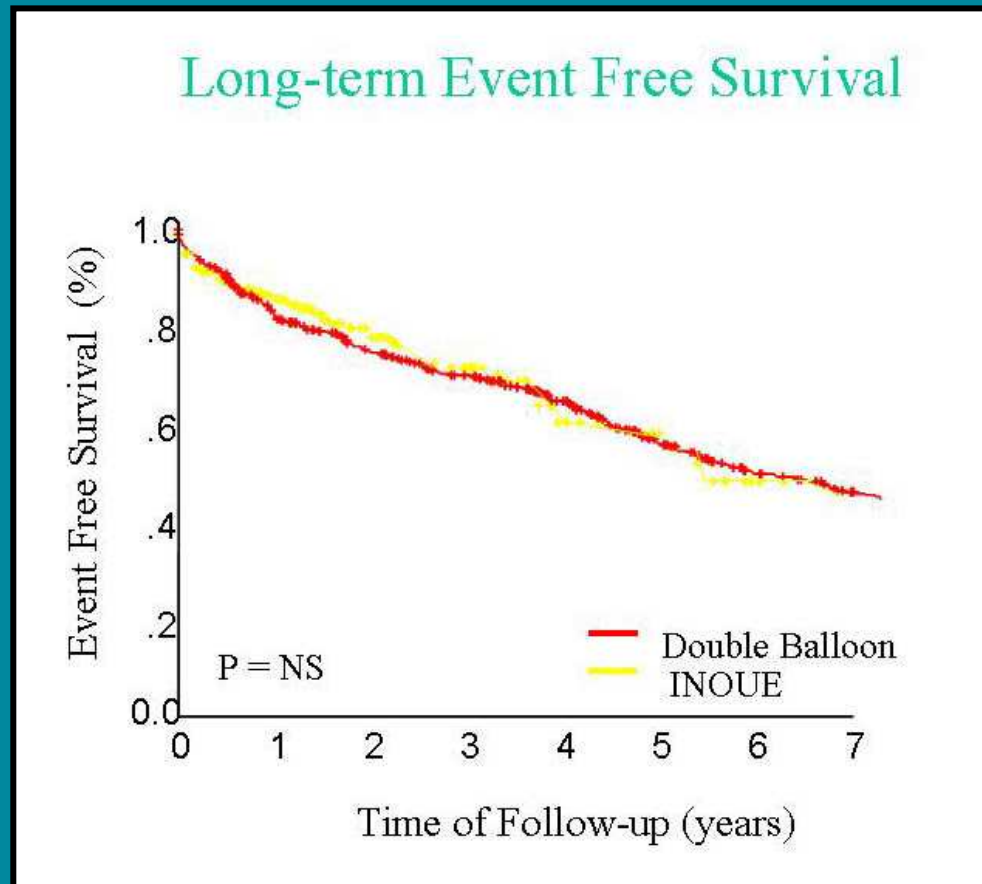
Comparison of post-PMV MVA between patients undergoing PMV using the double-balloon technique versus those with Inoue PMV

Percutaneous mitral balloon valvuloplasty using the double-balloon technique: immediate and long-term follow-up results



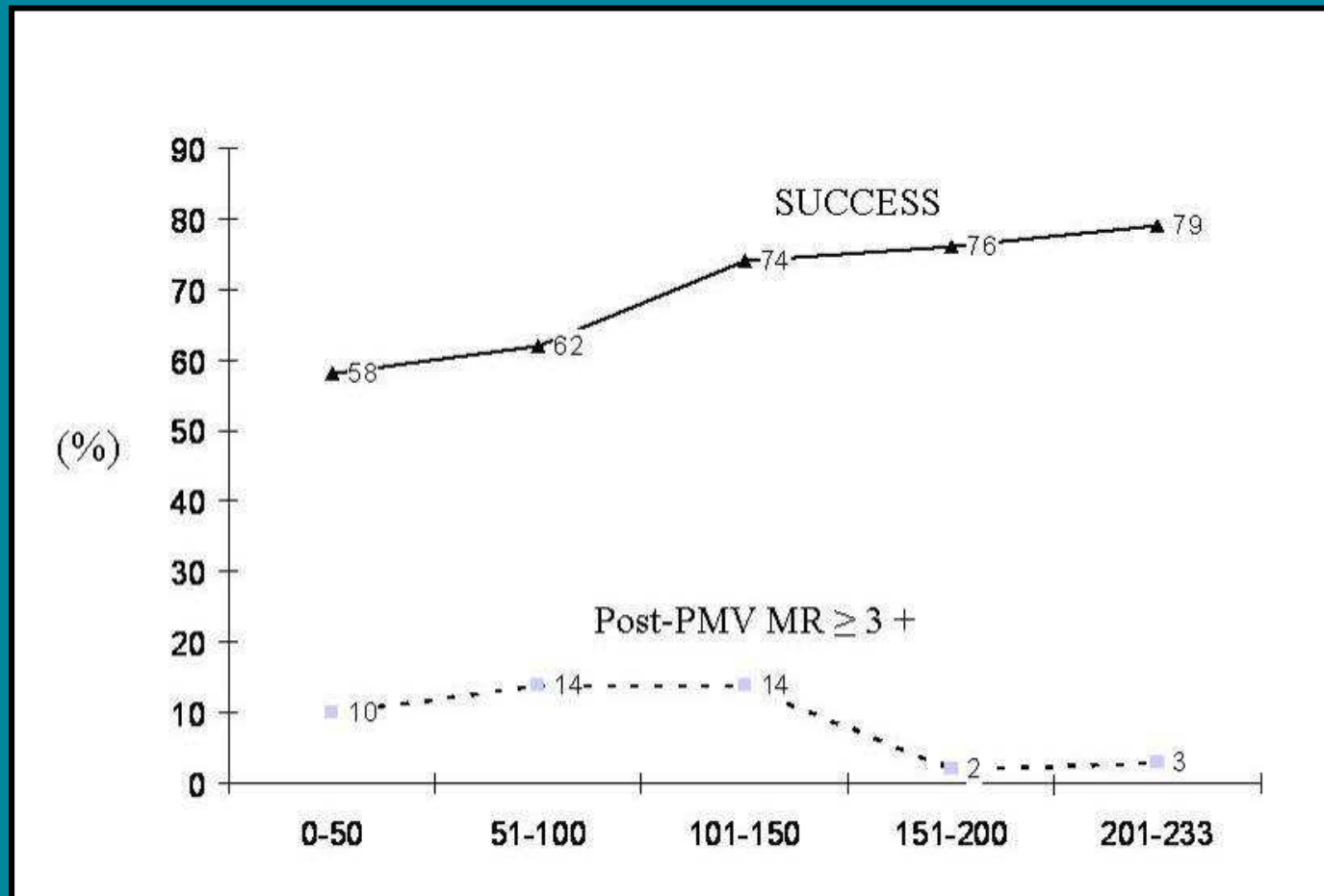
Kaplan–Meier survival curves of patients following PMV with the double-balloon and Inoue techniques

Percutaneous mitral balloon valvuloplasty using the double-balloon technique: immediate and long-term follow-up results



Kaplan–Meier event-free survival curves of patients following PMV with the double-balloon and Inoue techniques

Percutaneous mitral balloon valvuloplasty using the double-balloon technique: immediate and long-term follow-up results



The learning curve for the Inoue PMV