

## Section 28

### Percutaneous aortic valve replacement

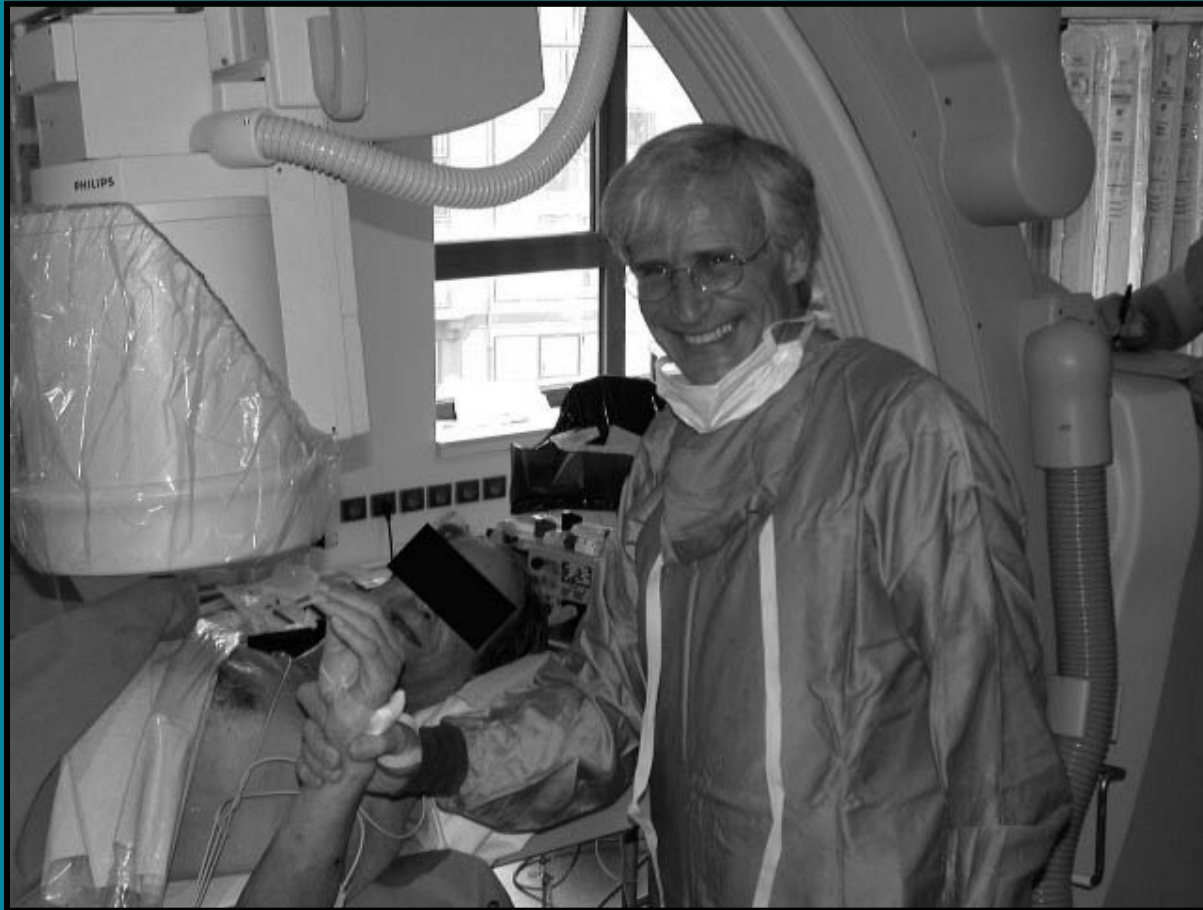**Alain Cribier, Vasilis Babaliaros, and Helene Eltchaninoff**

## Percutaneous aortic valve replacement



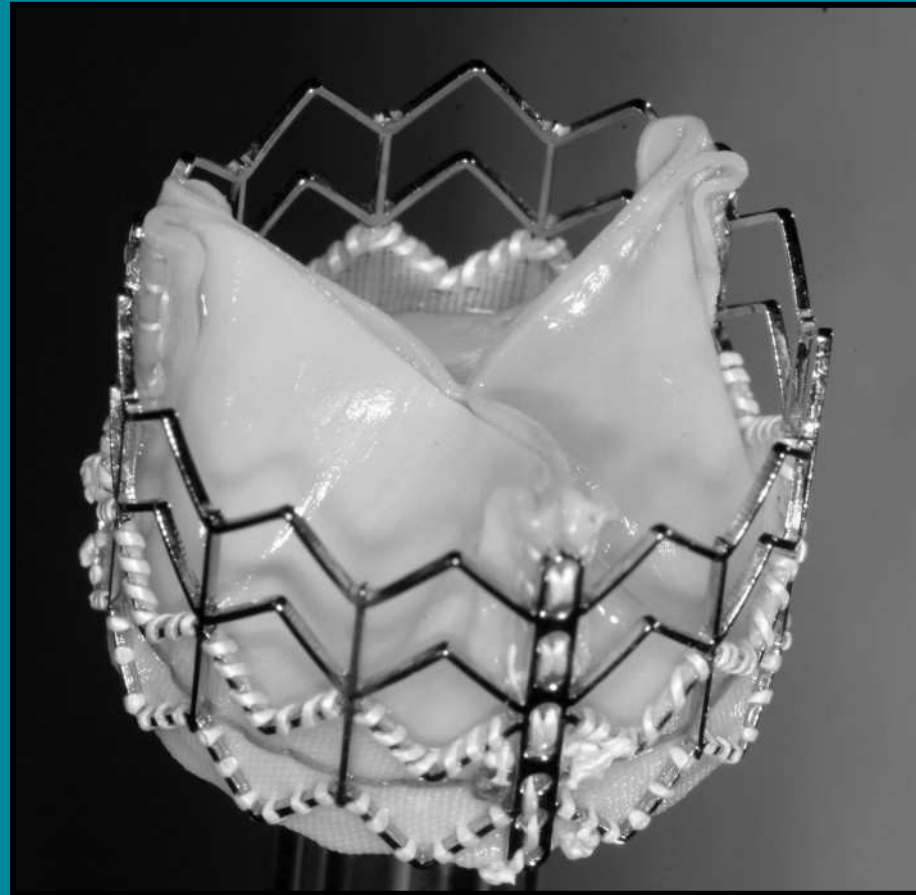
A commemorative photograph with Mrs S. at the TransCatheter Cardiovascular Therapeutics meeting, 29 September 2004

## Percutaneous aortic valve replacement



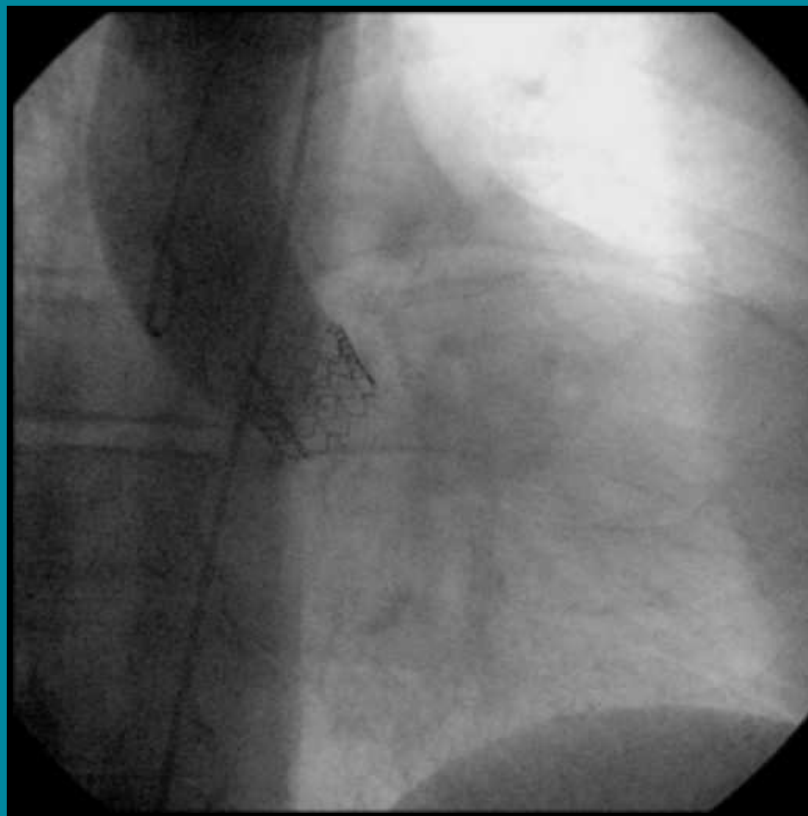
Mr S. and Alain Cribier after the landmark case, 16 April 2002

## Percutaneous aortic valve replacement



The current PHV we are using to implant humans

## Percutaneous aortic valve replacement



This supra-aortic angiogram, showing excellent position of the PHV within the native valve and no aortic regurgitation, was taken during our most recent implantation in the RECAST trial