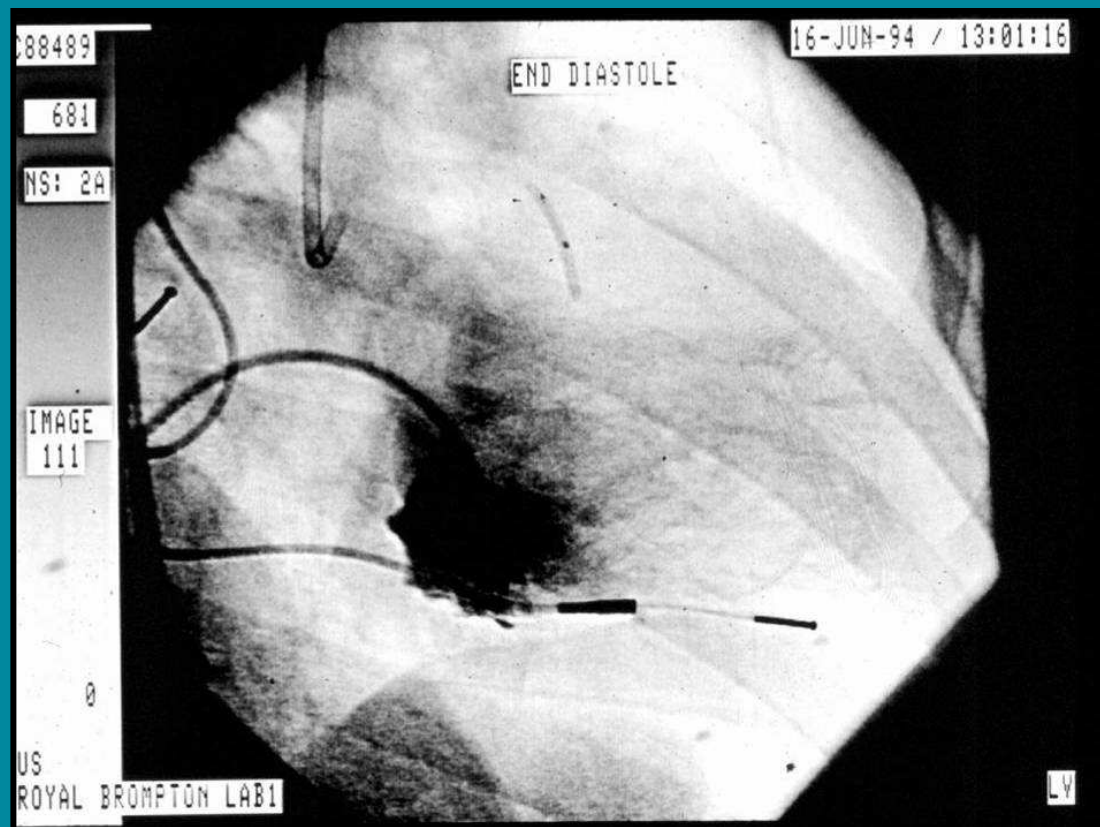


Section 29

Catheter-based septal ablation for patients with hypertrophic obstructive cardiomyopathy

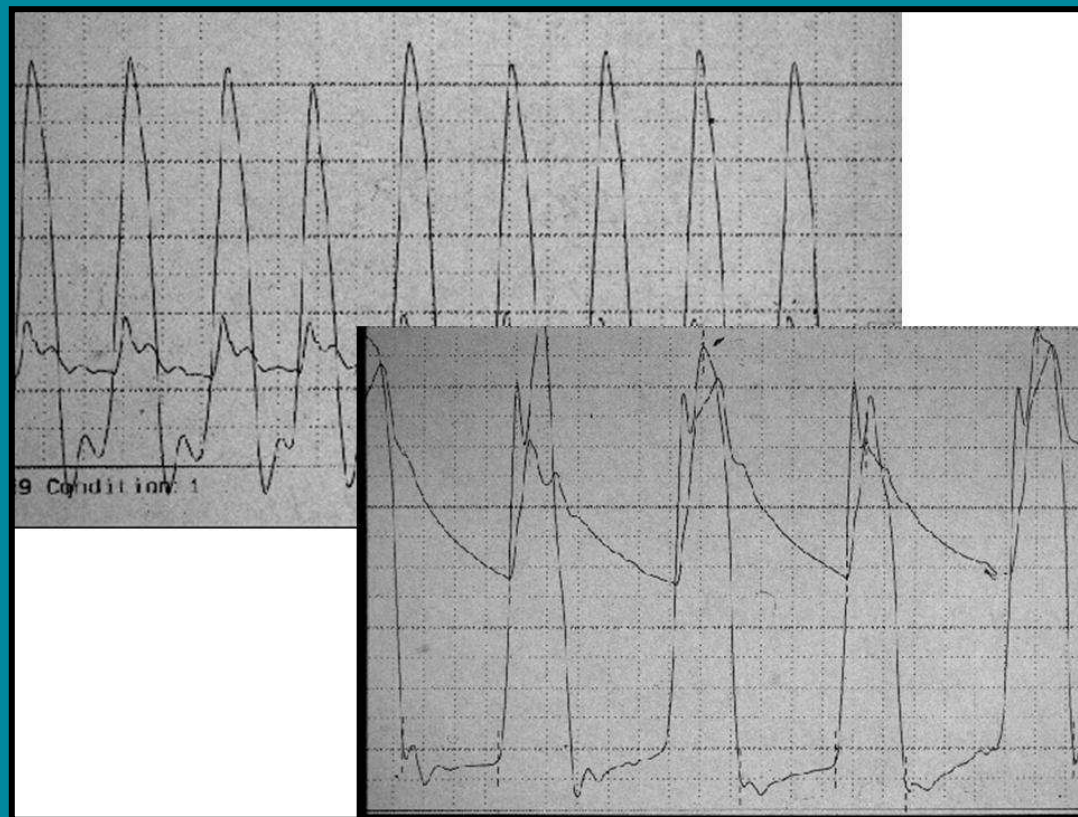Ulrich Sigwart

Catheter-based septal ablation for patients with hypertrophic obstructive cardiomyopathy



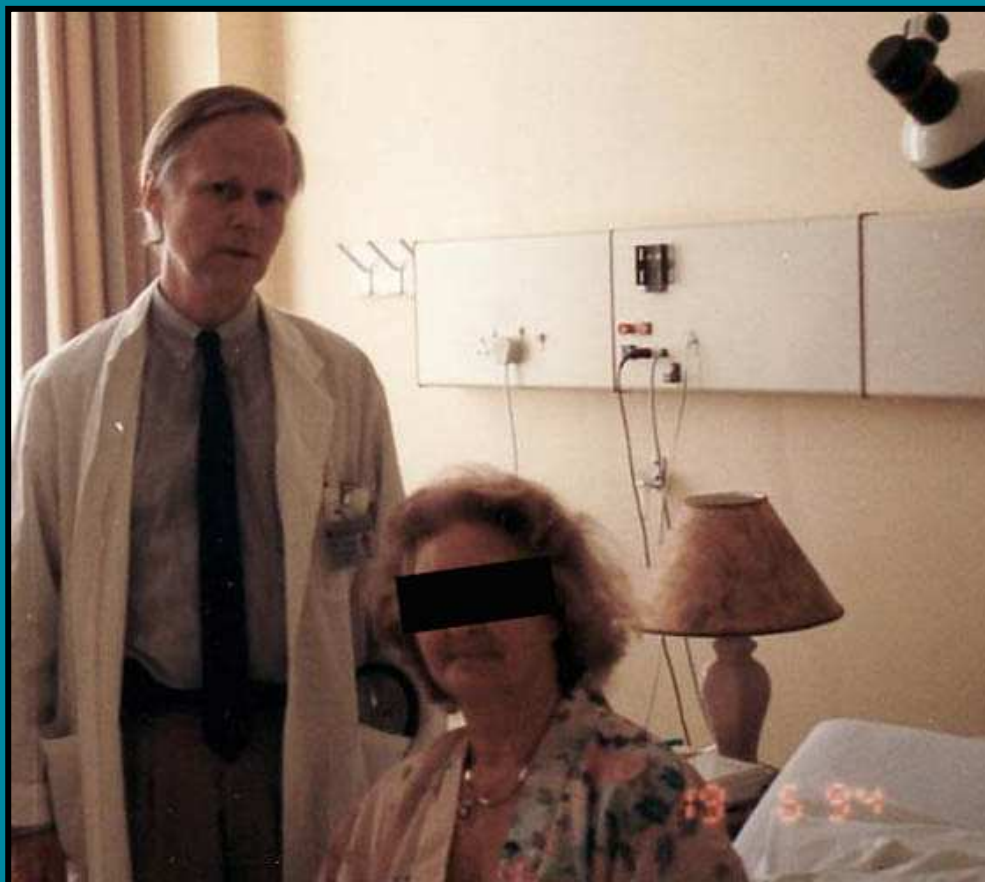Angiogram of the first ever septal ablation for hypertrophic obstructive cardiomyopathy at the Royal Brompton Hospital on 16 June 1994

Catheter-based septal ablation for patients with hypertrophic obstructive cardiomyopathy



Left ventricular and aortic pressure tracing before (left) and after (right) alcohol ablation of the first septal perforator branch

Catheter-based septal ablation for patients with hypertrophic obstructive cardiomyopathy



The first patient undergoing septal ablation for hypertrophic obstructive cardiomyopathy before hospital discharge on the third day after the procedure



Group photograph taken in Zurich in 1997 on the twentieth anniversary of interventional cardiology, featuring many of the pioneers featured in this slide set